

Oral and Periodontal Manifestations of Tuberculosis

Surekha Rathod¹, Farooque Khan², Anubha Raj³

How to cite this Article:

Rathod S, Khan F, Raj A, Oral and Periodontal Manifestations of Tuberculosis. Arch CranOroFac Sc 2015;4(1):4-7.

Source of Support: Nil.

Conflict of Interest: Nil.

INTRODUCTION

Tuberculosis is considered as "king of diseases" in Vedas and it has been mentioned by Sushruta and Chakra in 600 B.C [1]. Tuberculosis which is a chronic granulomatous infectious disease caused by Mycobacterium tuberculosis. Extrapulmonary tuberculosis is a rare entity, occurring in 10% to 15% of all cases [2]. Presently, Tuberculosis remains the leading cause of death worldwide from a single infectious organism. Approximately 32% of the population in the world is infected with tuberculosis and it is estimated that around 2 million people die annually from this treatable disease [3]. In India, the average prevalence of all forms of tuberculosis has been reported to be 5.05 per 1,000, the prevalence of smear-positive cases is 2.27 per 1,000 and the average annual incidence of smear-positive cases is 84 per million [4]. With the introduction of effective drug therapy, oral manifestations of tuberculosis have become so rare that this manifestation of the disease is often forgotten [5,6]. Oral tuberculosis can be primary or secondary. Primary oral tuberculous lesions are extremely rare and generally occur in young adults with associated caseation of the dependent lymph nodes; the lesion itself remains painless in most cases [7,8]. In contrast to this, secondary oral tuberculosis is seen in about 0.05% to 1.5% of cases and usually in older adults [9,10]. In oral tuberculosis, tongue is the most commonly affected site; other sites include the lip, cheek, soft palate, uvula, gingiva and alveolar mucosa. The lesions are seen as superficial ulcers, patches, induration of soft tissue or even lesions within the jaw in the form of tuberculous osteomyelitis [11].

MECHANISM

The mechanism of primary inoculation into the oral mucous membrane is not clearly understood. One reason for the rare occurrence of tuberculosis of the gingiva may be that the intact squamous epithelium of the oral cavity resists direct penetration by bacilli. This resistance has been attributed to the thickness of the oral epithelium, the cleansing action of saliva, local pH and antibodies in saliva [12]. Even if the onset of infection is by hematogenous spread, injured or inflamed tissue tends to localize



www.acofs.com

Use the QR Code scanner to access this article online in our database

Article Code: ACOFS0041

bloodborne bacteria. However, the mode of entry of the organism may be through a break in the mucous membrane caused by local trauma [13]. Where the infection involves bone, the mode of entry is thought to be through an extraction socket. However, there is general consensus that secondary tuberculosis spreads by a hematogenous route [14].

TUBERCULOSIS

1. TUBERCULOUS GINGIVITIS

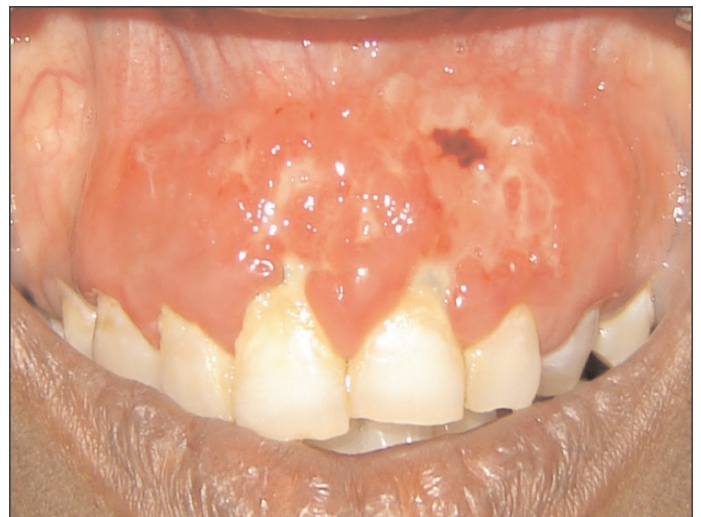

Figure.1: Tubercular gingival lesion

Tubercular gingival lesions (Figure.1) may present as exuberant and granulating or as mucosal erosions. Sometimes these lesions may be seen simultaneously with marginal periodontitis [15]. Chronic desquamative gingivitis is associated with chronic infections affecting the gingiva, the most common being tuberculosis. Case reports of gingival tuberculosis appearing as diffuse gingival enlargement [16], instead of the usual manifestation as an ulcer or localized granular mass, have also been documented in the literature.

2. TUBERCULOUS ULCER (Figure.2)

The common manifestation of oral tuberculosis is an ulcerative lesion of the mucosa. The lesion may be preceded by an opalescent vesicle or nodule which may breakdown as a result of caseation necrosis to form an ulcer [17].

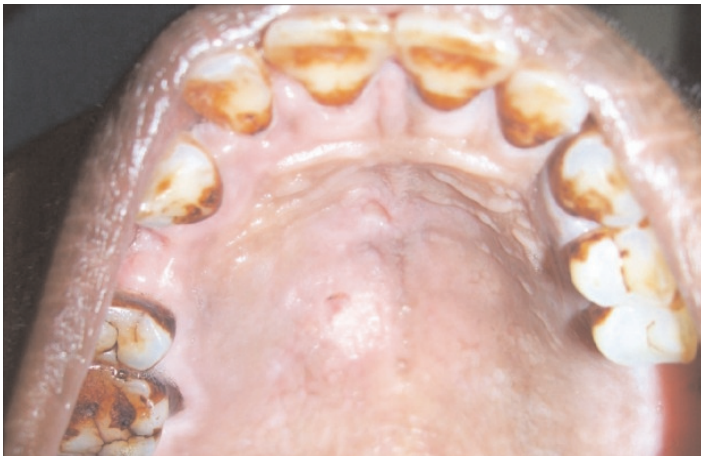

Figure.2:Tuberculous ulcer affecting palatal mucosa

3.TUBERCULOMA(Figure.3)

Tuberculosis may also involve the bone of the maxilla or mandible. One common mode of entry for the micro-organisms is into an area of periapical inflammation by way of the bloodstream (Anachoresis) [18]

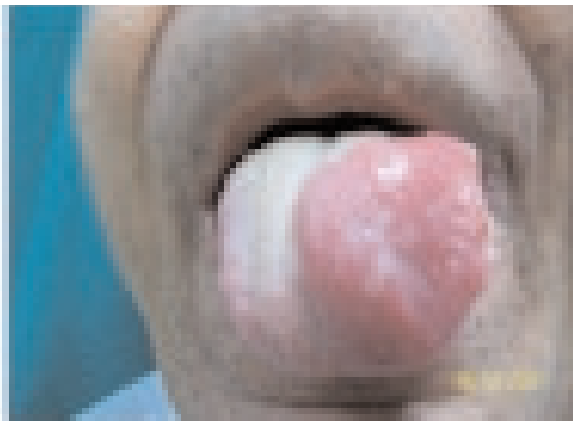


Figure. 3:Tuberculoma of Tongue

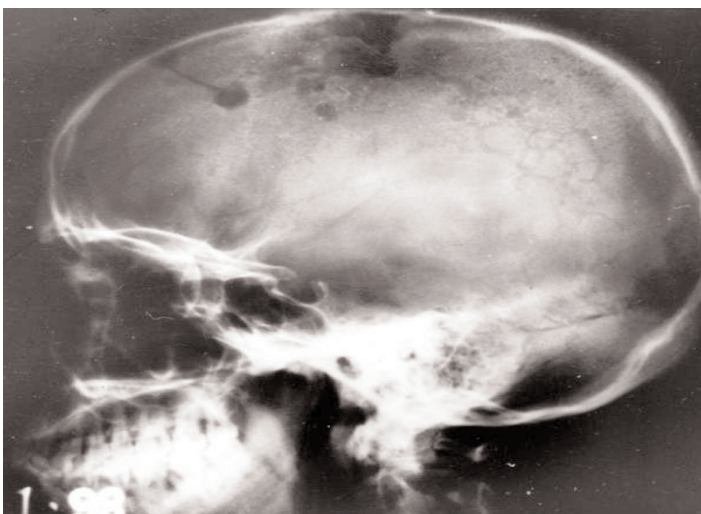


Figure. 4: Tuberculous osteomyelitis

4. TUBERCULOUS OSTEOMYELITIS(Figure.4)

Diffuse involvement of the maxilla or mandible may also occur, usually by haematogenous spread of infection, but sometimes by direct extension or even after tooth extraction [18]. The involvement of the mandible by TB infection is extremely rare as it contains less cancellous bone.

5. TUBERCULOUS LYMPHADENITIS

Tuberculosis of the lymphatic system is one of the most common of all extra-pulmonary tuberculosis, second only to tuberculous pleurisy. Its involvement of the cervical lymph nodes has been known for centuries as scrofula or the king's Evil. Tuberculous lymphadenitis predominantly occurs in females and in the younger age groups [19].

6. TUBERCULOUS SIALADENITIS

Tuberculous parotitis was first described in 1981 by Kuruvilla. Tuberculous parotitis with pulmonary infection is seen more commonly, but primary type of isolated parotid tuberculosis is seen very rarely [20]. Tuberculous parotitis occurs in 2.5% - 10% of parotid gland lesion even in countries where the disease is endemic such as India [21]. It most commonly presents as a localized mass, resulting from infection of intracapsular or pericapsular lymph nodes. It may also present as an acute sialadenitis with diffuse glandular enlargement.

EVIDENCES SIGNIFYING INTERRELATIONSHIP BETWEEN PERIODONTITIS & TUBERCULOSIS

A mild, painless, specific type of gingivitis associated with pulmonary tuberculosis was described by Cahn [22]. Cipes examined more than one thousand tuberculous patients and found a high incidence of characteristic gingivitis which varied in severity and extent proportionately to the pulmonary involvement. A definite association between pulmonary tuberculosis and periodontal lesions was also reported by Kramer and Brody [23]. They also reported periodontal bone changes, and were later supported by Goadby [24], who attributed these bone changes in the jaw to a loss of lime salts and a subsequent formation of granulation tissue. A general withdrawal of calcium salts from the bony system associated with pulmonary tuberculosis might cause a horizontal wasting of the alveolar process. This theory of demineralization of bone in cases of pulmonary tuberculosis seems to be unfounded. A second group of investigators have found, in tuberculous patients, an increased occurrence and extent of the commonly recognized types of periodontal diseases.

The third group of reports is headed by Tanchester and Sorrin's thorough investigation of 1,500 tuberculous patients plus a large number of healthy controls. They did not find any pathognomonic dental or periodontal signs of tuberculosis, nor did they observe more dental or periodontal disease in tuberculous than in healthy individuals.

DIAGNOSTIC TECHNIQUES**DIAGNOSTIC TOOL METHOD /INFERENCE [25]****1. TUBERCULIN SKIN TEST[TST]****a. Heaf test**

It includes multiple samples of testing serum over the flexor-surface of the forearm in a circular pattern of six. Read at 3-7 days.

b. Mantoux test

Tuberculin units are injected intradermally and read 48-72 hours later. Positive when induration of 5-15 mm is seen.

2. Radiographs

Areas of calcifications, cavities or radiolucency (darkened areas). Infiltrates or consolidation can easily be evaluated on radiographs.

3. Staining**a. Ziehl- Nelson Staining**

Acid fast bacilli are seen as bright red rods against blue, green or yellow background.

b. Auramine fluorescence

Visualises acid-fast bacillias bright rods against dark background using fluorescent microscope.

4. Enzyme linked immunosorbent Assays**(ELISA)**

Detects the presence of IgG and IgM.

Culture

a. Lowenstein - Jensen media (LJ media)

b. BACTEC

TREATMENT and PREVENTION

Immunization with viable Mycobacterium Bovis, BCG is the most widely used preventive measure to control tuberculosis worldwide. Administered to newborns in a single dose, it prevents severe disease and reduces mortality among children from miliary and meningeal disease [26]. Various Anti mycobacterial drugs [27] used in treatment are:

FIRST LINE DRUGS

1. Ethambutol
2. Pyrazinamide
3. Isoniazid
4. Rifamycins

MECHANISM OF ACTION

Inhibits arabinosyl transferase,

Inhibits fatty acid synthetase,

Inhibits fatty acid synthetase,

Binds to RNA Polymerase and inhibits transcription

SECOND LINE DRUGS

1. Cycloserine

2. Ethionamine

3. Aminoglycosides

Streptomycin

MECHANISM OF ACTION

Inhibits monomer synthesis,

Inhibits fatty acid synthetase,

Binds to 30s ribosomal units and inhibit translation

CONCLUSION

Tuberculosis infection of the gingivae is relatively rare; oral lesions would most commonly be secondary to pulmonary tuberculosis. Hence, to characterize oral lesions as primary tuberculosis, a thorough examination to rule out other primary sites should be attempted. With the recent increase in the incidence of tuberculosis, clinicians need to be aware of this possibility, consider tuberculosis in the differential diagnosis of gingival enlargement and, thus, play a role in the early detection of this disease.

REFERENCES

1. Shamimul Hasan et.al, Tuberculosis - A common disease with uncommon oral features Report of two cases with a detailed review of literature, Proceedings of the World Medical Conference.
2. Memon GA, Khushk IA. Primary tuberculosis of tongue. J Coll Physicians Surg Pak 2003; 13(10):604-605.
3. Smith KC, Armitige L, Wanger A. A review of tuberculosis: reflections on the past, present and future of a global epidemic disease. Expert Rev Anti Infect Ther 2003; 1(3):483-491.
4. Chakraborty AK. Epidemiology of tuberculosis: current status in India. Indian J Med Res 2004; 120(4):248-276.
5. Waldman RH. Tuberculosis and the atypical mycobacteria. Otolaryngol Den Clin North Am 1982; 15(3):581-596.
6. Tyldesley WH. Oral tuberculosis - an unusual presentation. Br Med J 1978; 2(6142):928.
7. Nwoku LA, Kekere-Ekun TA, Sawyer DR, Olude OO. Primary tuberculous osteomyelitis of the mandible.

- J Maxillofac Surg 1983; 11(1):46-48.
8. Smith WH, Davies D, Mason KD, Onions JP. Intraoral and pulmonary tuberculosis following dental treatment. *Lancet* 1982; 1(8276):842-844.
 9. Weaver RA. Tuberculosis of tongue. *JAMA* 1976; 235(22):2418.
 10. Woolfe M. Secondary tuberculous ulceration of the tongue: a case report. *Br Dent J* 1968; 125(6):270-271.
 11. Rao TV, Satyanarayana CV, Sundareshwar B, Reddy CR. Unusual form of tuberculosis of lips. *J Oral Surg* 1977; 35(7):595-596.
 12. Memon GA, Khushk IA. Primary tuberculosis of tongue. *J Coll Physicians Surg Pak* 2003; 13(10):604-605.
 13. Mani NJ. Tuberculosis initially diagnosed by asymptomatic oral lesions. Report of three cases. *J Oral Med* 1985; 40(1):39-42.
 14. Rinaggio J. Tuberculosis. *Dent Clin North Am* 2003; 47(3):449-465.
 15. Bjorlin G. Oral Tuberculosis: *Odontologisk Revy*, 18: 395-399.
 16. Bangalore Varadhan Karthikeyan, Avani Raju Pradeep, C.G. Dileep Sharma. Primary tuberculous Gingival Enlargement: A Rare Entity. *Journal of Canadian Dental Association* 2006; 72(7): 645-648.
 17. S.R. Prabhu and S.k. Sengupta. Bacterial infections due to mycobacteria A. Tuberculosis. *Oral diseases in the tropics*. Oxford university press 1993: 195- 202.
 18. Shafer WG, Hine MK, Levy BM. *A Textbook of Oral Pathology*; 5th edition; WB Saunders Company, Philadelphia.
 19. Tan KK. Tuberculosis lymphadenitis in Singapore. *Sing Med J* 1988; 29; 441-416.
 20. Selcuk A, Oruk V, Dere H, Boztepe F, Seckin S: Tuberculous parotitis: Can be left silent for a long time. *KBB-Forum* 2006; 5(3):130-132.
 21. Birkent H, Karahatay S, Akcam T, Durmaz A, Ongoru O: Primary parotid Tuberculosis mimicking parotid Neoplasm: A case report. *Journal of Medical Case Reports* 2008;2:62-63.
 22. Cipes, B. J.: Oral Hygiene in Relation to Tuberculosis, *D. Cosmos* 1926;68:50.
 23. Kramer, C. S.: Osseous Trophic Changes in the Jaws and Palate in the Tuberculous, *J. A. D. A.* 1925; 12: 1117.
 24. Goadby, K.: *Diseases of the Gums and Oral Mucous Membrane*, ed. 4, London, 1931, Oxford University Press.
 25. Kanwar Deep Singh Nanda, Anurag Mehta, Mohita Marwaha, Manpreet Kalra, Jasmine Nanda: A Disguised Tuberculosis of the oral Buccal mucosa. *Journal of Clinical and Diagnostic Research* 2011;5 (2):357-360.
 26. Rodregues LC, Diwan VK, Wheeler JG. Protective effect of BCG against Tuberculous meningitis and miliary tuberculosis: a meta-analysis. *Int J Epidemiology* 1993;22:1154-1158.
 27. Abramowicz M. (ed). *Drugs for tuberculosis. Treat Guidel Med Lett.* 2004;2(28):83-88.

AUTHORS

1. Dr .Surekha Rathod,
Professor,
Department of Periodontology ,
VSPM Dental College,
Nagpur, Maharashtra, India
Email: drsurekhar@gmail.com
2. Dr. Farooque Khan,
Post Graduate Student,
Department of Periodontology ,
VSPM Dental College,
Nagpur, Maharashtra, India
3. Dr. Anubha Raj
Department of Periodontology ,
VSPM Dental College,
Nagpur, Maharashtra, India

